

Tumours of the Submandibular Salivary Gland: a Clinicopathologic Review of Cases over a 17-year period

WL Adeyemo¹, OF Ajayi², CC Anunobi³, MO Ogunlewe¹, AL Ladeinde¹, OG Omitola², FB Abdulkareem³

ABSTRACT

Objective: This study presents a clinicopathologic review of cases of submandibular salivary gland tumours at the Lagos University Teaching Hospital, Nigeria, over a period of 17 years.

Methods: The records of all patients with histological diagnosis of submandibular salivary gland tumours at the Lagos University Teaching Hospital over a period of 17 years (January 1990 to December 2006) were retrospectively reviewed. Parameters studied included; age and gender of patients, symptoms and duration of symptoms and histological diagnosis.

Results: A total of 36 patients with submandibular gland tumours were seen during the period. Male-to-female ratio was 1.8:1 (male = 23, female = 13). Mean age (\pm SD) at presentation was 43 (\pm 19) years (age range, 17 – 84 years). There were 19 malignant tumours and 17 benign ones. Pleomorphic adenoma (36.1%) was the most frequent tumours, followed by adenoid cystic carcinoma (11.1%), anaplastic carcinoma (11.1%) and malignant lymphoma (11.1%). Patients with histological diagnosis of malignant tumours were significantly older than those with benign tumours ($p = 0.01$). Most patients (80.6%) presented with painless swelling.

Conclusion: Malignant submandibular salivary gland tumours were slightly more than the benign ones in the studied population. Painful swelling or ulceration is indicative of a malignant submandibular gland tumour.

Tumores de la Glándula Salival Submandibular: una Revisión Clínico-patológica de Casos por un Período de 17 Años

WL Adeyemo¹, OF Ajayi², CC Anunobi³, MO Ogunlewe¹, AL Ladeinde¹, OG Omitola², FB Abdulkareem³

RESUMEN

Objetivo: Este estudio presenta una revisión clinicopatológica de casos de tumores de la glándula salival submandibular en el Hospital Docente de la Universidad de Lagos, Nigeria, por un periodo de 17 años.

Métodos: Se revisaron retrospectivamente las historias clínicas de todos los pacientes con el diagnóstico histológico de los tumores de la glándula salival submandibular en el Hospital Docente de la Universidad de Lagos, correspondientes a un periodo de 17 años (de enero de 1990 a diciembre de 2006). Los parámetros estudiados incluyeron: la edad y el género de los pacientes, síntomas y duración de síntomas, y diagnóstico histológico.

Resultados: Un total de 36 pacientes con tumores de la glándula de submandibular fueron atendidos durante ese periodo. La proporción varón:hembra fue 1.8:1 (varones = 23, hembras = 13). La edad promedio (\pm SD) al momento de su presentación fue 43 (\pm 19) años (rango de edad, 17–84 años). Hubo 19 tumores malignos y 17 benignos. El adenoma pleomórfico (36.1%) fue el tipo de tumor más frecuente, seguido por el carcinoma cístico adenóideo (11.1%), el carcinoma anaplástico (11.1%) y el linfoma maligno (11.1%). Los pacientes con diagnóstico histológico de tumores malignos eran

From: ¹Departments of Oral and Maxillofacial Surgery, ²Oral Pathology and Biology, and ³Morbid Anatomy, College of Medicine, University of Lagos, Nigeria.

Correspondence: Dr WL Adeyemo, Department of Oral and Maxillofacial Surgery, College of Medicine, University of Lagos, PMB 12003, Lagos, Nigeria. E-mail: lanreadeyemo@yahoo.com.

significativamente de más edad que los que tenían tumores benignos ($p = 0.01$). La mayoría de los pacientes (80.6%) presentaban hinchazón sin dolor.

Conclusión: Los tumores malignos de la glándula salival submandibular fueron ligeramente mayor en número que los benignos en la población estudiada. Hinchazón dolorosa o la ulceración dolorosas son indicios de un tumor maligno de la glándula submandibular.

West Indian Med J 2009; 58 (5): 389

INTRODUCTION

The submandibular gland is the second largest salivary gland in the human body. Clinical studies of tumours of the submandibular gland comprising large numbers of patients are rare, although, this organ harbours most of the non-neoplastic diseases of the major salivary glands (1). Lying within the anatomical triangle of the same name, the submandibular gland has often been overshadowed by the parotid gland for two main reasons (2). Firstly, parotid gland lesions are more commonly encountered than those of the submandibular glands (2 - 4). Secondly, the challenging anatomy of the parotid gland, made possible by the interposing facial nerve, has consistently generated more interest and study than the anatomy of the submandibular gland (2).

This study presents the clinicopathologic review of cases of submandibular salivary gland tumours at the Lagos University Teaching Hospital, Nigeria, over a period of 17 years (January 1990 to December 2006) with a view to highlighting the age, gender and presenting complaints of patients as well as histological types.

SUBJECTS AND METHODS

The records of all patients with a histological diagnosis of submandibular salivary gland tumours after surgical excision of the gland at the Lagos University Teaching Hospital over a period of 17 years (January 1990 to December 2006) were retrieved from the Departments of Oral and Maxillofacial Surgery, Oral Pathology and Biology, and Morbid Anatomy of the same institution. Parameters studied included: age and gender of patients, symptoms and duration of symptoms, and histological diagnosis. Two of the authors (OFA and CCA) re-evaluated the haematoxylin and eosin stained histological sections. Data were analysed using the SPSS for Windows (version 12.0; SPSS Inc, Chicago, IL) statistical software package. Descriptive statistics and test of significance (chi-square and student *t*-test) were used as appropriate. The *p* value ≤ 0.05 was considered statistically significant.

RESULTS

A total of 36 patients with histological diagnosis of submandibular salivary gland tumours were seen during the period. Male-to-female ratio was 1.8:1 (male = 23, female = 13). Mean age (\pm SD) at presentation was 43 (\pm 19) years (age range, 17 - 84 years). There were 19 malignant tumours (52.8%, male = 13, female = 6) and 17 benign (47.2%, male = 10, female = 7) ones. Pleomorphic adenoma (36.1%) was the most frequent tumours, followed by adenoid cystic

carcinoma (11.1%), anaplastic carcinoma (11.1%) and malignant lymphoma (11.1%) [Table 1]. Patients with the histo-

Table 1: Characteristics of patients with Submandibular Salivary Gland Tumours

Age of patients (years)	
Mean (SD)	Range
43 (19)	17 - 84
Sex	
Male (%)	Female (%)
23 (63.8)	13 (36.2)
Histological Diagnosis	
Types	Number of patients (%)
Benign	
Pleomorphic adenoma	13 (36.0)
Warthin's tumour	1 (2.8)
Oncocytic adenoma	1 (2.8)
Angiomatous fibrous histiocytoma	1 (2.8)
Fibrolipoma	1 (2.8)
Malignant	
Adenocystic carcinoma	4 (11.1)
Anaplastic carcinoma	4 (11.1)
Lymphoma	4 (11.1)
Mucocpidermoid carcinoma	2 (5.6)
Adenocarcinoma	2 (5.6)
Squamous cell carcinoma	2 (5.6)
Carcinoma ex-pleomorphic adenoma	1 (2.8)

gical diagnosis of malignant tumours (mean, 47.7 \pm 21 years; range, 19 - 84 years) were significantly older than those with the histological diagnosis of benign tumours [mean, 37.7 \pm 14 years; range 17 - 62 years] [$p = 0.01$] (Fig. 1).

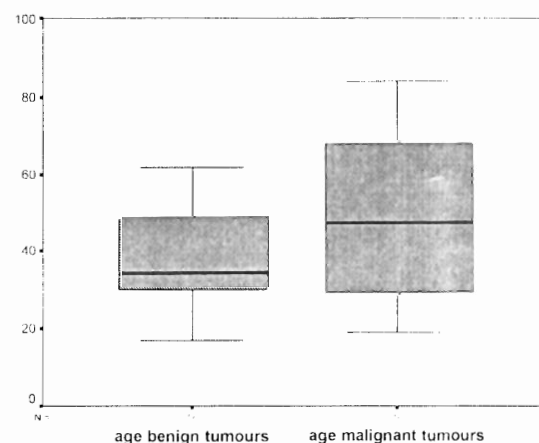


Fig. 1: Box plot comparative analysis of age of patients with benign and malignant tumours ($p < 0.05$). Medians and quartiles are displayed in the box plot, and the extreme values are represented by the horizontal lines outside the box.

Progressive painless swelling (80.6%) was the most common mode of presentation followed by painful swelling (11.1%) and painful ulceration (8.3%). All patients ($n = 7$, 19.4%) with either painful swelling or painful ulceration as primary symptoms at presentation had a diagnosis of malignant tumour. Duration of the lesion prior to presentation could be ascertained in 24 patients and ranged between 1 and 360 months (Table 2). Patients with malign-

Table 2: Duration of Submandibular Gland Tumours before presentations in 24 patients

Duration (months)	Number of patients (%)
1 – 12	10 (41.7)
> 12 – 24	5 (20.8)
> 36 – 60	4 (16.7)
> 60 – 360	5 (20.8)
Total	24 (100)

ant lesions presented earlier (mean = 25.8 months; range, 2–120 months) than those with benign ones [mean, 64.4 months; range 1–360 months] ($p = 0.004$).

DISCUSSION

Tumours of the salivary glands constitute approximately 3% of all head and neck neoplasms (10). Approximately 70% to 80% of these tumours are encountered in the parotid gland (6, 7). However, approximately 10% of all salivary gland tumours are localized in the submandibular gland, with a high rate of malignant tumours (8, 9). Tumours of the submandibular gland are rare. This is reflected in the relative absence of reports of a large series of patients in the literature (Table 3) [10–15].

A great variety of different tumour entities are reported in the submandibular gland. These may either be epithelial or non-epithelial tumours (14). Epithelial tumours of the submandibular gland are composed of a histologically diverse group of neoplasms with differing epidemiological characteristics and different biological behaviour with the relative absence of clinical symptomatology (9, 14). The submandibular triangle is also one of the most frequent sites of occurrence for haematologic malignancies.

Both Hodgkin and non-Hodgkin's lymphomas and various types of leukaemias show early manifestations of disease with nodal enlargements in the submandibular region (10, 14).

In the present study, malignant tumours (52.8%) were more frequently seen than their benign counterparts (47.2%). This is in agreement with reports of Weber *et al* (16) and Rapidis *et al* (14), but is at variance with those of Preuss *et al* (5) and others (10, 13) who reported more benign tumours than malignant ones. Regarding the most common malignant tumours in the present series, there were equal rates for adenoid cystic carcinoma, anaplastic carcinoma and lym-

phoma. Preuss *et al* (5) in a recent study reported equal rates for adenocystic carcinoma and lymphoma in their series. While adenocystic carcinoma was reported to be the most common malignant tumour by Weber *et al* (16), Rallis *et al* (13) and Rapidis *et al* (14) reported squamous cell carcinoma and adenocarcinoma respectively.

Pleomorphic adenoma (76.5%) was the most common benign tumour and overall, the most common tumour (36%) in the present series. Pleomorphic adenoma is widely reported to be the most common benign tumour of the submandibular gland (5, 10, 13, 14, 17). As observed in the present series, apart from pleomorphic adenoma being the most common, there are a great histological variety of benign tumours that have been reported arising from the submandibular gland. These include Warthin's tumour, oncocytomas, neurolimmomas, lymphoepithelial lesions *etc* (5, 13, 14).

Patients with the histological diagnosis of malignant tumours were significantly older than those with histological diagnosis of benign tumours in the present series. This finding suggests that malignant tumours of the submandibular gland predominantly affect patients of the older age group and benign ones predominantly affect patients of younger age group.

In the present study, progressive painless swelling (80.6%) was the most common mode of presentation followed by painful swelling (11.1%) and painful ulceration (8.3%). All patients with either painful swelling or painful ulceration as primary symptoms at presentation had malignant tumours. Benign salivary gland tumours are characterized by slow-growing painless swelling (18). In addition, they do not ulcerate and they are not associated with nerve signs (18). In contrast, malignant salivary gland tumours are sometimes fast-growing and may be hard in consistency, may ulcerate, invade bone and present with cranial nerve palsies (18).

The fact that patients with malignant tumours presented earlier to the clinic than patients with benign tumours may also be related to the discomfort associated with pain and ulceration of malignancies. Most patients in the studied environment did not present early to hospital unless they experienced pain, ulceration or other discomfort.

Surgical excision is reported to be a safe and effective treatment of submandibular gland tumours (5, 13, 14). Benign submandibular gland tumours manifest a mild course of disease and local excision along with the gland is a safe and effective mode of treatment (14). In contrast, the prognosis of malignant submandibular tumours depends on several factors (14). Stage of disease at presentation and tumour histology seem to be the most important (14, 19). However, encouraging results for an improved rate of survival have recently been reported by Storey *et al* (20), when aggressive combined treatment with surgery and postoperative radiotherapy with higher than 60 Gy was applied.

CONCLUSIONS

Pleomorphic adenoma was the most common tumours of the submandibular salivary gland in the studied population. Overall, malignant submandibular salivary gland was slightly more than the benign ones. Patients with a histological diagnosis of malignant tumours were significantly older than those with histological diagnosis of benign tumours. Painful swelling or ulceration is indicative of malignant submandibular gland tumour.

REFERENCES

1. Elies M, Laskawi R, Agrebe C, Schott A. Surgical management of non-neoplastic diseases of the submandibular gland. A follow-up study. *Int J Oral Maxillofac Surg* 1996; **25**: 285-89.
2. Wenig HM. Atlas of Head and Neck Pathology. Philadelphia: W.B. Saunders; 1993.
3. Conley J, Myers E, Cole R. Analysis of 115 patients with tumours of the submandibular gland. *Ann Otol Rhinol Laryngol* 1972; **81**: 323-30.
4. Tran L, Sadeghi A, Hanson D, Juillard G, Mackintosh R, Calcattera TC et al. Major salivary gland tumours: treatment results and prognostic factors. *Laryngoscope* 1986; **96**: 1139-44.
5. Preuss SF, Klusmann JP, Witterkindt C, Drebber U, Beutner D, Guntinas-Lichius O. Submandibular gland excision: 15 years of experience. *J Oral Maxillofac Surg* 2007; **65**: 953-7.
6. Batsakis JG. Carcinomas of the submandibular and sublingual glands. *Ann Otol Rhinol Laryngol* 1986; **95**: 211-2.
7. Shaha AR, Webber C, DiMaio T, Jaffe BM. Needle aspiration biopsy in salivary gland lesions. *Am J Surg* 1990; **160**: 373-6.
8. Ichimura K, Nibu K, Tanaka T. Nerve paralysis after surgery in the submandibular triangle: Review of University of Tokyo Hospital Experience. *Head Neck* 1997; **19**: 48-53.
9. Spiro RH. Salivary neoplasms: Overview of a 35-year experience with 2, 807 patients. *Head Neck Surg* 1986; **8**: 177-84.
10. Gott YH, Sethl DS. Submandibular gland excision: a five-year review. *J Laryngol Otol* 1998; **112**: 269-73.
11. Nagler RM, Laufer D. Tumors of the major and minor salivary glands: Review of 25 years experience. *Anticancer Res* 1997; **17**: 701-7.
12. Pinkston JA, Cole P. Incidence rates of salivary gland tumors: Results from a population-based study. *Otolaryngol Head Neck Surg* 1999; **120**: 834-40.
13. Rallis G, Mourouzis C, Zachariades N. A study of 55 salivary gland excisions. *Gen Dent* 2004; **52**: 420-3.
14. Rapidis AD, Stavrianos S, Lagogiannis G, Faratzis G. Tumors of the submandibular gland: Clinicopathologic analysis of 23 patients. *J Oral Maxillofac Surg* 2004; **62**: 1203-8.
15. Yasumoto M, Shibuya H, Suzuki S, Ishii J, Amagasa T, Ida M et al. Computed tomography and ultrasonography in submandibular tumors. *Clin Radiol* 1992; **46**: 114-20.
16. Weber RS, Byers RM, Petit B, Wolf P, Ang K, Luna M. Submandibular gland tumors. Adverse histological factors and therapeutic implications. *Arch Otolaryngol Head Neck Surg* 1990; **116**: 1055-60.
17. Laskawi R, Ellis M, Arglebe C, Schott A. Surgical management of benign tumors of the submandibular gland: A follow-up study. *J Oral Maxillofac Surg* 1995; **53**: 506-8.
18. Cawson RA, Odell EW. Essentials of oral pathology and medicine. London: Churchill Livingstone; 1998.
19. Vander Poorten VL, Balm AJ, Hilgers FJ, Tan IB, Loftus-Coll BM, Keuss RB et al. Prognostic factors for long term results of the treatment of patients with malignant submandibular gland tumours. *Cancer* 1999; **85**: 2255-64.
20. Storey MR, Garden AS, Morrison WH, Eicher SA, Schechter NR, Ang KK. Postoperative radiotherapy for malignant tumors of the submandibular gland. *Int J Radiat Oncol Biol Phys* 2001; **51**: 952-8.