

The Role of Transrectal Ultrasound-Guided Fine-Needle Aspiration Biopsy in the Diagnosis of Prostate Cancer: Sextant Versus Extended Protocol

Abisola E. Oliyide, Kehinde H. Tijani, Emmanuel A. Jeje, Charles C. Anunobi¹, Adekunle A. Adeyomoye², Rufus W. Ojewola, Moses A. Ogunjimi, Taiwo O. Alabi

Departments of Surgery, ¹Anatomic and Molecular Pathology and ²Radiology, Lagos University Teaching Hospital, Lagos, Nigeria

Abstract

Aim and Objectives: The aim of this study is to compare the prostate cancer detection rates of sextant and extended transrectal ultrasound (TRUS)-guided fine-needle aspiration biopsy (FNAB) protocols. **Materials and Methods:** This was a prospective study of 96 patients investigated for prostate cancer. An extended 10-aspiration TRUS-guided FNAB using a 22G Echotip Chiba needle was performed. Inclusion criteria included the presence of one or more of the following: Abnormal digital rectal examination (DRE) findings, persistently elevated prostate specific antigen, and abnormal prostatic imaging. A set of traditional sextant aspirations were carried out as well as four laterally guided aspirations taken from the middle base of the peripheral zone on either side. The cancer detection rates of sextant and extended (combination of sextant and lateral) FNAB protocols were determined and compared. The value of $P < 0.05$ was considered statistically significant. **Results:** The overall cancer detection rate was 24%. Benign cases were reported in 71.8% of patients and 4.2% reported as suspicious. Of the 23 patients' aspirations positive for malignancy, 16 (69.6%) were detectable by the sextant protocol while the lateral protocol detected 21 (91.3%). Two cancers were detected by the sextant protocol only (where the lateral technique was negative for malignancy), 7 cancers were detected by the lateral protocol only while 14 cancers were positive in both the sextant and lateral protocols. The extended protocol showed a statistically significant 30.4% increase in cancer detection over the traditional sextant ($P = 0.007$). **Conclusion:** The extended protocol rather than the sextant protocol should be offered to patients who require FNAB of the prostate as the optimum FNAB protocol.

Keywords: Detection rate, extended, fine-needle aspiration biopsy, prostate cancer, sextant

INTRODUCTION

Prostate cancer is the most frequently occurring malignancy in men after middle age.^[1] It constitutes a great health-care burden due to its high incidence and mortality rates.^[2] Furthermore, the cost incurred as regard to detection and treatment of this disease is a significant economic burden.^[2,3] The main indications for prostate biopsy are persistently elevated prostate-specific antigen (PSA), abnormal digital rectal examination (DRE) findings and abnormal findings on prostatic imaging.

Diagnosis is the key to initiating early treatment. Fine-needle aspiration biopsy (FNAB) and core needle biopsy (CNB) are the major techniques used in tissue diagnosis.^[4] Torp-Pedersen *et al.*^[5] were the first to report the results of transrectal ultrasound (TRUS)-guided prostate biopsy with an 18G spring action biopsy needle device and this has since been adjudged

as the gold standard. The trauma associated with CNB led to more studies on the less invasive technique of FNAB. FNAB has thus evolved from the transperineal route first introduced by Ferguson^[6] which was popularised by Franzen^[7] with the development of his needle guide for the transrectal route. Tijani *et al.*^[8] also carried out a digitally guided transrectal FNAB which was one of the first studies in the Nigerian population.

The method of prostate biopsy has also undergone many changes from targeted biopsies^[9] at palpable abnormalities through to the systematic sextant method.^[10] Presti *et al.*^[11] took

Address for correspondence: Dr. Abisola E. Oliyide, Department of Surgery, Lagos University Teaching Hospital, Lagos, Nigeria. E-mail: aquaaby@yahoo.co.uk

This is an open access article distributed under the terms of the Creative Commons Attribution-NonCommercial-ShareAlike 3.0 License, which allows others to remix, tweak, and build upon the work non-commercially, as long as the author is credited and the new creations are licensed under the identical terms.

For reprints contact: reprints@medknow.com

How to cite this article: Oliyide AE, Tijani KH, Jeje EA, Anunobi CC, Adeyomoye AA, Ojewola RW, *et al.* The role of transrectal ultrasound-guided fine-needle aspiration biopsy in the diagnosis of prostate cancer: Sextant versus extended protocol. Niger Postgrad Med J 2017;24:236-9.

Access this article online

Quick Response Code:



Website:
www.npmj.org

DOI:
10.4103/npmj.npmj_131_17

two lateral extra biopsies at the base and mid gland on each side in addition to the sextant method thereby producing a 10 core biopsy. It was found that the traditional sextant technique missed 20% of cancers. These, however, relate to CNB. To the best of our knowledge, there has been no study to compare sextant with extended protocols using FNAB. Therefore, the aim of this study was to shed more light on this area.

MATERIALS AND METHODS

This prospective study was carried out amongst 96 men who were being investigated for prostate cancer at our centre. Approval was obtained from the Human Research and Ethics Committee of the Lagos University Teaching Hospital situated in the hospital administration building. The HREC assigned number is ADM/DCST/HREC/1994 and approval was obtained on the 18th of November 2014 spanning 1 year. An informed written consent was also obtained from all the patients.

Inclusion criteria were the presence of one or the combination of persistently elevated PSA, abnormal DRE findings and abnormal findings on imaging studies (ultrasound scan, computed tomography or magnetic resonance imaging) of the prostate. Exclusion criteria were patients who declined consent or had symptomatic urinary tract infections or that were already on treatment for prostate cancer. Patients were recruited on a consecutive basis on the fulfilment of criteria and documented consent. Patients on antiplatelet drugs such as aspirin and clopidogrel were asked to discontinue the drug for a minimum of 10 days before the biopsy. Oral antibiotics (500 mg ciprofloxacin bd and 400 mg metronidazole tds) were commenced 48 hours before the procedure and continued for 5 days as per unit protocol. Intravenous access was secured before all procedures. No systemic sedatives or analgesic agents were administered. All procedures were done as day cases.

Prostate biopsy was performed following the insertion of dulcolax suppositories into the rectum the night before the procedure to reduce the faecal load. Patients were usually placed in the left lateral decubitus position with knees and hips flexed at 90° for biopsies. An arm board attached parallel to the table and a pillow between the knees allowed patients to maintain this position. The buttocks were flush with the edge of the table to allow instillation of anaesthesia and manipulation of the probe without obstruction. Local anaesthesia (20 ml of intrarectal 2% xylocaine gel massaged onto the prostate) was used, and preliminary DRE was carried out and documented. The TRUS probe (Mindray product, DP-2200 model with a 7.5 MHz transducer, China) with a condom worn on it and a needle guide attached to it was lubricated with sonogel and was then gently inserted into the rectum. TRUS evaluation of the prostate was carried out and documented. Each patient then received injection of 5 ml of 2% plain xylocaine (Rotex Medical brand, Germany) bilaterally at the basolateral region, only at the junction between the prostate and the seminal vesicle using a 22G spinal needle introduced through the needle guide. Additional 5 ml of 2% plain xylocaine was injected at the apex of the prostate.

FNAB was done with the patient in the left lateral position using a size 22G, 20 cm long Echotip Skinny needle with a Chiba tip (Cook medical brand). This was inserted through the needle guide on the transrectal probe [Figure 1]. When the needle entered the prostate, about 10 small amplitude to-and-fro movements of the needle were performed to loosen the target tissue. Negative pressure was obtained by pulling on the syringe plunger (20 ml syringe) to aspirate the material into the needle. Before withdrawing the needle from the prostate, the negative pressure was released, a most important step that ensured that the aspirated material remained in the needle and did not enter the barrel of the syringe, where it would have been irretrievably lost. A set of traditional sextant aspirations was done. Furthermore, four laterally guided aspirations were taken in the peripheral zone at the middle and the base (lateral aspirations). This made up an extended 10 aspiration protocol [Figure 2]. Suspicious nodules were also aspirated separately. Each aspiration was smeared on two slides and immediately fixed in 95% alcohol and transported to the cytopathologist. The cytology stains used included Papanicolaou, haemoxilin and eosin. The FNAB slides were analysed by a single uropathologist. The results of the FNAB were reported according to the Royal College of Pathologists scheme, i.e., positive for malignant cells, negative for malignant cells, suspicious or insufficient sample.^[12]

It was ensured that patients not on urethral catheter voided urine before discharge to detect any haematuria or urinary retention. Subsequently, all patients were discharged home after 2 hours of observation if no complication(s) warranting admission for further care was noticed. They were counselled to note the onset and duration of any problem(s) arising from the procedure. The importance of completing earlier prescribed antibiotics was also emphasised.

They were all followed up on their mobile phones in between the time of the procedure and the first clinic visit after the procedure (usually 1 week) for any complication(s). The second clinic visit after the procedure was usually 1 week thereafter and was dedicated to the review of their investigation results and complication(s). All complications noted were documented.

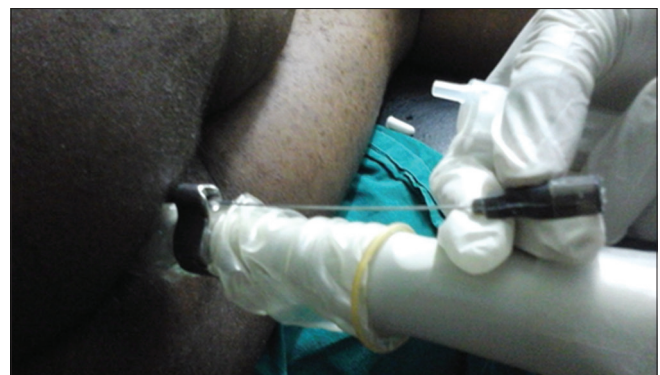

Figure 1: Transrectal ultrasound probe, needle guide and fine-needle *in situ* within the anorectum for preparation of fine-needle aspiration cytology

The data were analysed using Statistical Package for the Social Sciences for Windows version 20.0 (IBM, Armonk, NY, USA). The value of $P < 0.05$ was taken as being statistically significant.

RESULTS

Ninety-six patients were recruited for the study. Ages of patients ranged from 47 to 80 years with a mean age of 64.96 ± 7.53 years. The peak age range was 61–70 years and accounted for 52.1% of the entire study population [Table 1]. The PSA range was 2.33–161.45 with a mean age of 14.89 ± 20.34 ng/ml.

Cytopathology of 23 (24%) of the 96 patients was reported as malignant, 69 (71.8%) as benign and 4 (4.2%) as suspicious [Figure 3].

Fourteen patients had both sextant and lateral aspirations positive for malignancy. Two (8.7%) malignancies were detected by the sextant aspirations only and not in the included lateral aspirations, while 7 (30.4%) were identified by the lateral aspirations alone and were missed by the sextant aspirations. Altogether, of the 23 diagnosed with malignancies, sextant technique detected 16 (69.6%), while 21 (91.3%) were detected by lateral aspirations with an increase of 30.4% in detection by the extended protocol [Figure 4].

The overall cancer detection rate by the extended technique (sextant plus lateral) was 23 (24%) as opposed to 16 (16.7%) with the sextant technique only [Figure 5]. There was statistically significant increase in detection of 30.4% by the extended over the sextant technique ($P = 0.007$).

DISCUSSION

In the past century, a lot of advances have been made with the advent of PSA measurement.^[13] This has led to a dramatic increase in the number of prostate biopsies being performed with a resultant increase in diagnosis of prostate cancer at an early stage. The gold standard for diagnosis remains tissue biopsy which has evolved over the years to include techniques involving the use of semi-automated Tru-cut biopsy needles as well as TRUS. Nevertheless, this has been fraught with a

number of undesirable effects and complications necessitating the need for less invasive techniques. These include haematuria, haematochezia, haemospermia, urinary retention, prostatitis, urinary tract infections and sepsis which may necessitate hospital admissions with the resultant economic impact.^[1]

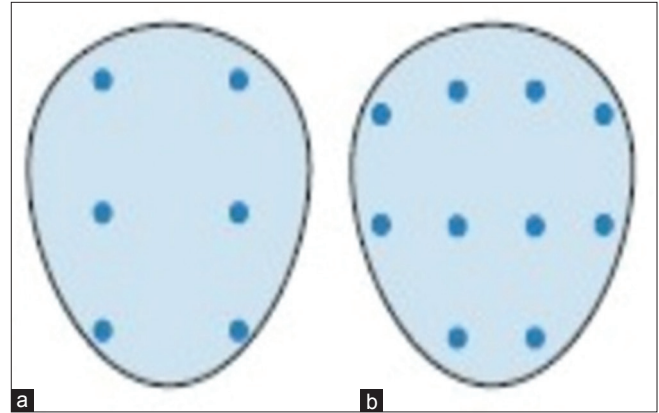


Figure 2: Schematic representation of sextant (a) and extended protocol (b)

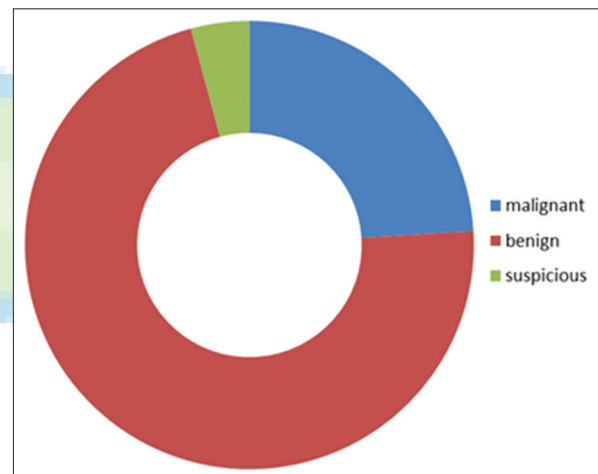


Figure 3: Distribution of cytopathological diagnosis

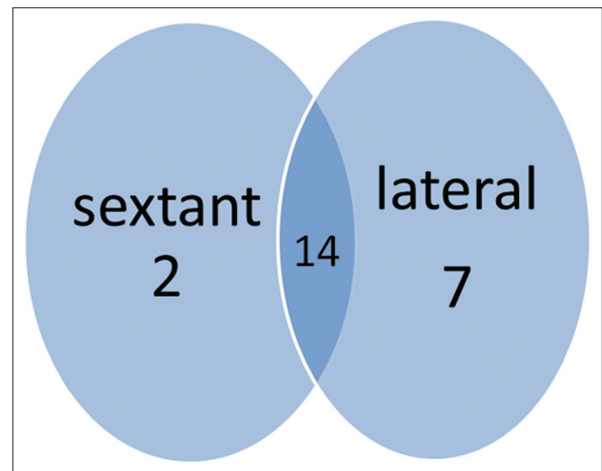


Figure 4: Pattern of cancer detection by sextant and extended fine-needle aspiration biopsy protocols

Table 1: Distribution of patients' characteristics

	<i>n</i> (%)
Age group (years)	
41-50	3 (3.1)
51-60	21 (21.9)
61-70	50 (52.1)
71-80	22 (22.9)
Total	96 (100)
Educational level	
Informal	1 (1.0)
Primary	4 (4.2)
Secondary	21 (21.9)
Tertiary	70 (72.9)
Total	96 (100)

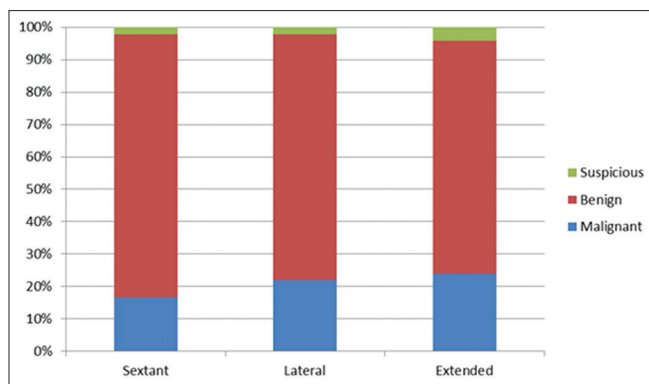


Figure 5: Comparison of detections by aspiration protocols

Apart from the reduced morbidity associated with FNAB, studies have shown that in the hands of experienced cytopathologists, it may be as helpful as the CNB.^[14] The peak incidence of the patients (52.1%) was in the 61–70 years age group with a mean age of 64.9 years. This buttresses the fact that it is a disease of ageing males. Other studies also noted similar distribution.^[1,3,8]

Of the 23 patients with malignant lesions on cytology, cancer detection rate was higher in the extended protocol in this study. While the traditional sextant cytology protocol only was positive in 16 cases (69.6%), the use of the extended protocol led to a 30.4% increase in the cancer detection rate ($P=0.007$). This is consistent with previous studies^[15,16] using core needle biopsies which emphasise the need for an extended protocol, especially in non-palpable cases. Two (8.7%) cases were detected by sextant aspirations alone while 7 cases (30.4%) were detected by lateral aspiration alone. These would have been missed if either protocol was used alone thus emphasising that both sextant and lateral aspirations complement each other and the extended aspiration protocol should be advocated. Majority of prostate cancers (70%) originate from the PZ (an area that may be poorly represented in the traditional sextant biopsy protocol as the biopsies are taken from the parasagittal segment of the prostate), sextant aspirations may, therefore, prove to be inadequate.^[17] The higher incidence of positive aspirates in the lateral protocol when compared with the sextant (91.3% vs. 69.6%) is consistent with these studies.

This study had one main limitation. Literature search was difficult as there was no record of any previous study comparing extended with sextant aspirations of the prostate. As a result, most comparisons have been made against studies involving core needle biopsies. This is applicable as these studies have been based on the same methodology of comparing sextant aspiration/core needle biopsies with the extended protocol aspirations/core needle biopsies [Figure 2].

CONCLUSION

With an improvement of 30.4% increase in the cancer detection rate using the extended FNAB protocol, this study, confirms that the addition of the lateral protocol to the traditional sextant

protocol significantly improves cancer detection in patients being evaluated for prostate cancer. This has long been seen in the evaluation of CNB protocols and now also rings true for FNAB protocols.

We, therefore, suggest that the extended protocol rather than the sextant protocol should be offered to patients who require FNAB of the prostate as the optimum FNAB protocol.

Acknowledgements

The authors would like to thank Dr. Jide Sobande for assistance with the statistical analysis.

Financial support and sponsorship

Nil.

Conflicts of interest

There are no conflicts of interest.

REFERENCES

- Crawford ED. Epidemiology of prostate cancer. *Urology* 2003;62:3-12.
- Brawer MK, Chetner MP, Beatie J, Buchner DM, Vessella RL, Lange PH, *et al.* Screening for prostatic carcinoma with prostate specific antigen. *J Urol* 1992;147:841-5.
- Jackson MA, Ahluwalia BS, Herson J, Heshmat MY, Jackson AG, Jones GW, *et al.* Characterization of prostatic carcinoma among blacks: A continuation report. *Cancer Treat Rep* 1977;61:167-72.
- Ragde H, Aldape HC, Bagley CM Jr. Ultrasound-guided prostate biopsy. Biopsy gun superior to aspiration. *Urology* 1988;32:503-6.
- Torp-Pedersen S, Lee F, Littrup PJ, Siders DB, Kumasaka GH, Solomon MH, *et al.* Transrectal biopsy of the prostate guided with transrectal US: Longitudinal and multiplanar scanning. *Radiology* 1989;170:23-7.
- Gillenwater J, Grayhack J, Howards S, Duckett J, editors. *Adult and Paediatric Urology*. 2nd ed. St. Louis: Mosby Year Book; 1991. p. 1288-309.
- Ekman H, Hedberg K, Persson PS. Cytological versus histological examination of needle biopsy specimens in the diagnosis of prostatic cancer. *Br J Urol* 1967;39:544-8.
- Tijani KH, Banjo AA, Adetayo FO, Osegbe DN. Fine needle aspiration biopsy cytology in the diagnosis of prostatic cancer: A Nigerian hospital experience. *Niger Med J* 2005;46:88-90.
- Hodge KK, McNeal JE, Stamey TA. Ultrasound guided transrectal core biopsies of the palpably abnormal prostate. *J Urol* 1989;142:66-70.
- Hodge KK, McNeal JE, Terris MK, Stamey TA. Random systematic versus directed ultrasound guided transrectal core biopsies of the prostate. *J Urol* 1989;142:71-4.
- Presti JC Jr., Chang JJ, Bhargava V, Shinohara K. The optimal systematic prostate biopsy scheme should include 8 rather than 6 biopsies: Results of a prospective clinical trial. *J Urol* 2000;163:163-6.
- Ali SZ, Leteurte E. The official nomenclature and terminologies in diagnostic cytopathology: History, evolution, applicability and future. *Ann Pathol* 2012;32:e3-7, 389-93.
- Brawer MK. Prostate-specific antigen: Current status. *CA Cancer J Clin* 1999;49:264-81.
- United Nations Publications. *World Population Prospects: The 2012 Revision*. Vol. 1. Comprehensive Tables 2013a; 23 (ST/ESA/SERA/336); 2013a. p. 2-142.
- Babaian RJ, Toi A, Kamoi K, Troncoso P, Sweet J, Evans R, *et al.* A comparative analysis of sextant and an extended 11-core multisite directed biopsy strategy. *J Urol* 2000;163:152-7.
- Babaian RJ. Extended field prostate biopsy enhances cancer detection. *Urology* 2000;55:453-6.
- McNeal JE, Redwine EA, Freiha FS, Stamey TA. Zonal distribution of prostatic adenocarcinoma. Correlation with histologic pattern and direction of spread. *Am J Surg Pathol* 1988;12:897-906.