

Evaluation of the Therapeutic Effects of Aloe Vera Gel on Alloxan-Induced Diabetic Rats

Imaga, N.O.A*, Ebuehi, O.A.T., Edom, J.J., Obomniru, G.E., and Oyadina, O.O.

Department of Biochemistry, College of Medicine, University of Lagos,
P.M.B. 12003, Idi-araba, Lagos, Lagos State, Nigeria

Address for Correspondence: Dr. N.O.A. Imaga; noaimaga@gmail.com

ABSTRACT

Background: *Aloe vera* gel (AVG) extract is commonly used as a home remedy for some diseases, including diabetes mellitus.

Objectives: This study is to determine the effects of pure *Aloe vera* (*Aloe babardensis*) gel on some biochemical, haematological and histological parameters in diabetic rats.

Methods: The rats were divided into six groups of six rats each. Diabetes mellitus was experimentally induced in rats by intraperitoneal administration of a single dose of alloxan monohydrate (170 mg/kg b.w.) following a 12 h fasting period. The Groups I and V received isotonic saline in a similar manner. The establishment of diabetes mellitus was confirmed by fasting blood glucose (FBG) level above 350mg/dl using a GlucoMetre (AccuChek Active). The AVG extract was administered for 14 days along with the metformin and alloxan drugs administered. Blood samples were taken from fasted rats. The effects of AVG on fasting blood, biochemical, haematological and oxidative stress parameters in the liver and histological examination of the liver, kidney and pancreas were evaluated.

Results: There was a decrease in blood glucose level in the AVG treated group and an improvement in the lipid profile, as well as some haematological parameters. In addition, oral administration of *Aloe barbadensis* gel decreased the level of MDA with a corresponding increase in the activities of CAT, SOD, GST and GSH levels in the liver tissue of diabetic rats.

Conclusion: These results suggest potent hypoglycaemic, hypolipidemic, antioxidant and therapeutic effects of Aloe Vera, beneficial as a herbal remedy for the treatment/management of diabetes mellitus.

Keywords: Diabetes, alloxan, *Aloe babardensis* gel; hypoglycaemic, hypolipidemic, antioxidant, rat

INTRODUCTION

Diabetes mellitus (DM), is still a serious health challenge all over the world, especially in developed and developing countries, with Type 2 diabetes mellitus now considered a worldwide epidemic. Recent statistics indicate that the global prevalence of diabetes mellitus for all age groups was estimated as 366 million in 2011, with a projected rise

to 522 million by 2030¹. Diabetes mellitus is a long-term metabolic disorder of multiple etiology characterized by chronic hyperglycaemia with disturbances of carbohydrate, fat and protein metabolism resulting from defects in insulin secretion and/or insulin action². The symptoms of diabetes are excessive urine production (polyuria), excessive thirst and increased fluid intake (polydypsia), blurred vision, unexplained weight loss and lethargy and excessive hunger (polyphugia)³.

It has been identified as one of the most important causes of complications, such as diabetic nephropathy, angiopathy, neuropathy, retinopathy, deficiency in the antioxidant defence system, and lipid profile disorders^{4,5}. In diabetes mellitus, chronic hyperglycemia produces multiple biochemical abnormalities, hyperlipidemia and diabetes-induced oxidative stress can play a role in the symptoms and progression of the disease^{6,7}. It has been reported that oxidative stress is also one of the major causes of pathophysiological conditions during diabetes. Moreover, persistent hyperglycaemia may lead to an exaggerated production of free radicals, especially reactive oxygen species (ROS), in tissues due to glucose oxidation and protein glycosylation⁸. To reduce the risk of late complications and negative outcomes of diabetes mellitus such as renal failure, blindness and limb amputation, the control of both blood glucose and lipid levels are important. The prevalence and complications of type 2 diabetes are increasing daily. The use of conventional drugs to treat metabolic disorders and the pathological consequences of diabetes further increases the complications because of the side effects and high costs of these drugs. Therefore, there is a need to develop alternative strategies for diabetes therapy. Natural products are useful alternatives because these compounds are believed to have fewer side effects. Many minor components of foods, such as secondary plant metabolites, have been shown to alter biological processes, which may reduce the risk of chronic diseases in humans⁹.

Many herbs, spices and other plant materials have been used to treat diabetes. A total of more than 400 species were reported to display hypoglycaemic effects, but few of these species have actually been investigated⁹. To date, 90 plants have been screened for hypoglycaemic properties at various research institutes on Diabetes, Endocrine and Metabolic Disorders all over the world¹⁰. These plants include *Trigonella foenum graecum*, *Allium cepa*, *Hemidesmus indicus*, *Syzgium cumini*, *Murraya koenigii* and *Aloe vera*^{10,11}.

Aloes have long been used all over the world for their various medicinal properties. *Aloe barbadensis* Miller (otherwise known as *Aloe vera*) is a perennial plant belonging to the family *Liliaceae* and with its origin in the North Africa. *Aloe vera* is one of the plants considered to have a hypoglycemic effect and many diabetic subjects take the gel, because of its hypoglycaemic effect¹². It has been used for many centuries for its curative and therapeutic properties and for its ability to treat hyperlipidaemia^{12,13}.

Aloe vera not only possesses hypoglycaemic activity but is also hypotensive, hepato-protective and also a blood purifier¹⁴. Moreover, *Aloe vera* reduces the intestinal absorption of water, helping to increase the occurrence of bowel movements. As a result, this plant is widely used as a laxative¹⁵. The hypoglycemic effects of *Aloe vera* have been investigated by various researchers. Ethanolic extracts of *Aloe vera* administered to Wistar albino rats with high blood glucose levels resulted in a significant decrease in the plasma glucose levels of the rats¹⁶.

In this study, the therapeutic effect of *Aloe babardensis* gel was investigated on some biochemical, haematological and antioxidant parameters, as well as on the histology of the liver, and kidney in alloxan-induced diabetic rats.

MATERIALS AND METHODS

Experimental Animals

Thirty-six healthy Wistar albino rats of both sexes, weighing 156.64 ± 7.91 g were used in the present study. They were purchased from the Animal Laboratory Centre, College of Medicine, University of Lagos, Nigeria. Before and during the experiment, the animals were maintained in a well-ventilated room with natural day-night cycle in polypropylene cages lined with husk in standard environmental conditions (temperature $22 \pm 5^\circ\text{C}$, and a 12:12 light: dark cycle) at the Animal Laboratory Centre, College of Medicine, University of Lagos, Lagos. The rats were allowed free access to water and rat chow, except when overnight fasting was required according to the experimental design, and allowed to acclimatize for two weeks prior to induction. All animal procedures were conducted in accordance with the standards set forth in the guidelines for the care and use of experimental animals by the Committee for the Purpose of Control and Supervision of Experiments on Animals and the National Institutes of Health.

Rats weighing 180 – 200g were randomly divided into six groups of six rats in each group:

Group I: Normal Control group → received 0.9% saline solution;

Group II: Diabetic Untreated group → received alloxan (170mg/kg b.w) once;

Group III: Metformin-treated group → received Alloxan + Metformin (7.14mg/kg b.w);

Group IV: *Aloe vera*-treated group → received Alloxan + *Aloe vera* gel (300mg/kg b.w);

Group V: *Aloe vera*-Control group → received 0.9% Saline solution + *Aloe vera* gel (300mg/kg b.w);

Group VI: *Aloe vera* pre-treated group → *Aloe vera* gel (300mg/kg b.w) for 2 weeks + Alloxan.

Body weight and fasting blood glucose levels of all the rats were determined before the start of the experiment. The body weights of control and experimental groups were recorded at an interval of one week till the completion of the experimental period (14days), at day 0, 7 and 14 days. Dosages were calculated as extrapolated doses for humans.

Induction of Experimental Diabetes

Diabetes mellitus was experimentally induced in the rats of Groups II, III and IV and VI, by intra-peritoneal injection of a single dose of alloxan monohydrate (170 mg/kg b.w) following a 12 h fast. After injection, they had free access to food and water and were given 5% glucose solution to drink overnight to counter hypoglycaemic shock. Groups I and V received 0.9% saline solution in a similar manner. The establishment of diabetes mellitus was confirmed by fasting blood glucose (FBG) levels above 350mg/dl, using a glucometer. The drug solutions were prepared freshly each time and orally administered intragastrically for a period of 14 days. The dosing schedule used was once per day.

Blood and Liver Tissues

At the end of the experimental period (14days) of treatment, rats were fasted overnight and blood was drawn from rats by retro-orbital sinus puncture method³³ with capillary tubes until sacrifice. The blood was collected in heparin-coated centrifuge tubes, centrifuged at 4000g for 5min, then plasma was separated in Eppendorf tubes and stored at -30°C . Whole blood was also collected in EDTA bottles and used for the determination of some haematological parameters (such as Hb, RBC, WBC, etc.), whereas separated plasma was used to determine the lipid profile and renal function parameters (electrolytes, urea and creatinine).

The rats were sacrificed by cervical dislocation, the liver and kidney were removed, washed with ice-cold 0.9 saline. The liver was divided into two parts, one part along with the other organs was used for the histological study and the other part was used for the assessment of lipid peroxidation (Malonaldehyde MDA, reduced glutathione, GSH, superoxide dismutase, SOD and catalase, CAT).

The effects of AVG on fasting blood glucose, lipid profiles, liver and renal function parameters, haematological parameters in blood and oxidative stress parameters in the liver were evaluated.

Biochemical Analysis

Assay of lipid profile and renal function tests.

The levels of cholesterol, triglycerides, LDL, HDL, protein, creatinine and urea, were measured in the plasma samples obtained from all the groups. The measurements were performed in accordance with the manufacturer protocols of the Randox diagnostic kits, UK. The concentrations of all the parameters were evaluated by colorimetry. The intensity of colouration was measured using the UV/Visible-Model-80-2106-00 spectrophotometer, Pharmacia Biotech, Cambridge, England.

Estimation of haematological parameters

The haemoglobin (Hb), red blood cell (RBC), and white blood cell count (WBC) were measured. The Hb level was measured using a hemoglobinometer. The RBC and WBC counts were made using a haemocytometer, according to earlier described methods by Van Kampen and Zijlstra¹⁷. The tests were carried out within 12h after collection of blood.

Estimation of Liver Protein

Protein content in the rat liver was estimated by the method of Lowry *et al.*¹⁸, using bovine serum albumin as standard.

Estimation of Lipid Peroxidation

The lipid peroxidation or the amount of malodialdehyde (MDA) in the liver, was measured by a method described by Okhawa, *et al.*¹⁹. The liver tissue was homogenized in ice-cold 0.1M phosphate buffer (pH7.2) and the absorbance was read at 532nm. The concentration of MDA, which was expressed as MDA per mg protein was determined.

Assay of Hepatic Reduced Glutathione (GSH)

The reduced glutathione was determined using DTNB as the colouring reagent and the method described by Beutler *et al.*²⁰. The absorbance was read at 412nm using a spectrophotometer and the GSH values were determined using the molar extinction coefficient of 13,600 cm⁻¹M⁻¹.

Determination of Hepatic Catalase (CAT) activity

The catalase activity was estimated in the liver homogenate by the method of Ugochukwu *et al.*,²¹. The specific activity of catalase is expressed in units of moles of H₂O₂ consumed/min/mg of protein. The difference in the absorbance at 240nm per unit time was used to determine the catalase activity. An extinction coefficient at 240nm H₂O₂ of 40.0M⁻¹cm⁻¹ was used for the calculation.

Determination of Hepatic Superoxide Dismutase (SOD) activity

Superoxide Dismutase activity was determined by its ability to inhibit the auto-oxidation of epinephrine determined by the increase in absorbance at 480nm as described by Misra and Fridovich²². Enzyme activity was calculated by measuring the change in absorbance at 480 nm for 5 min. $\Sigma = 4020M^{-1}cm^{-1}$.

Histological study

The liver and kidney tissues from each animal were processed using light microscopy. The tissue sections were fixed in 10% neutral buffered formalin and embedded in paraffin. The paraffin sections were then stained with hematoxylin-eosin (H&E). Mallory Trichrome was used for detecting the collagen deposition in the hepatic tissue via a Leica DMRB/E light microscope (Heerbrugg, Switzerland).

Statistical Analysis

The statistical analysis was performed using the GraphPad Prism Program (GraphPad Software, version 5.0 Inc., San Diego, USA). The results were expressed as arithmetic mean (M) ± Standard Deviation (S.D) (n=4-6), and total variation present in a set of data was analysed through one-way analysis of variance (ANOVA). This measure was supplemented by individual comparison between the different treatments by applying Turkey's multiple tests for pair wise comparisons at 95% (p<0.05) confidence level.

RESULTS

Effect of *Aloe barbadensis* gel on the body weights and blood glucose levels in control and diabetic rats.

The effect of *Aloe barbadensis* gel on body weight and blood glucose levels in the control and diabetic

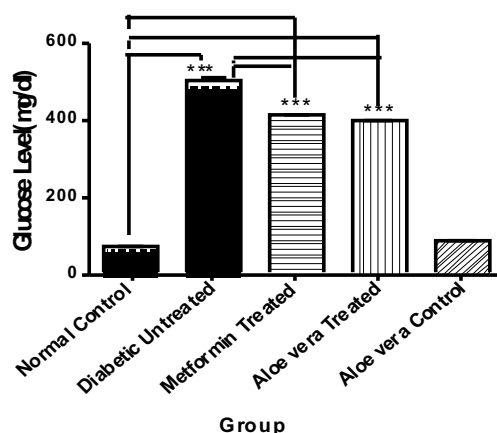
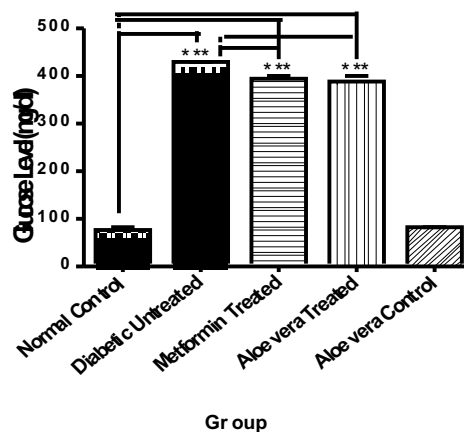
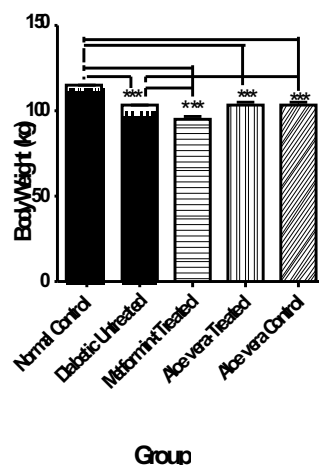


Fig. 1: The Effect of Oral Administration of *Aloe barbadensis* gel on body weight and fasting blood glucose in Alloxan-induced Diabetic Rats at the end of a 14-day experimental period (a 2-week study). Data represent means ± S.D. (n = 4-6). Comparison was done between the normal control and diabetic untreated rats, and between Aloe-treated and diabetic untreated rats. NB: *p<0.05, **p<0.01 and ***p<0.001.

Effect of *Aloe barbadensis* gel on lipid profile in control and diabetic rats

The lipid profile showed an elevation in the levels of total cholesterol (TC), triglycerides (TG), low density lipoprotein (LDL-C) levels in diabetic untreated group when compared with the normal control and Aloe-treated groups, but decreased value of high density lipoprotein (HDL-C), while the *Aloe vera* showed declination in the Lipid profile levels and increased HDL-C levels denoting its hypolipidaemic effects (Fig. 2).

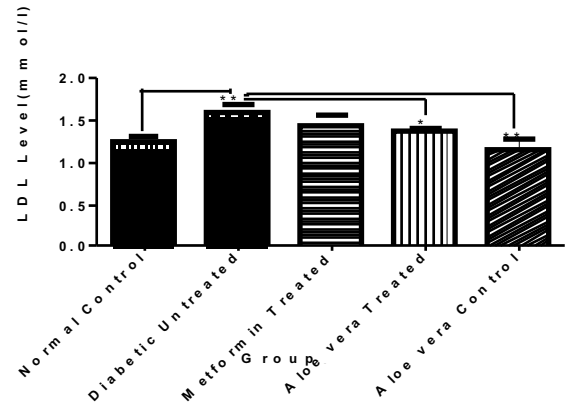
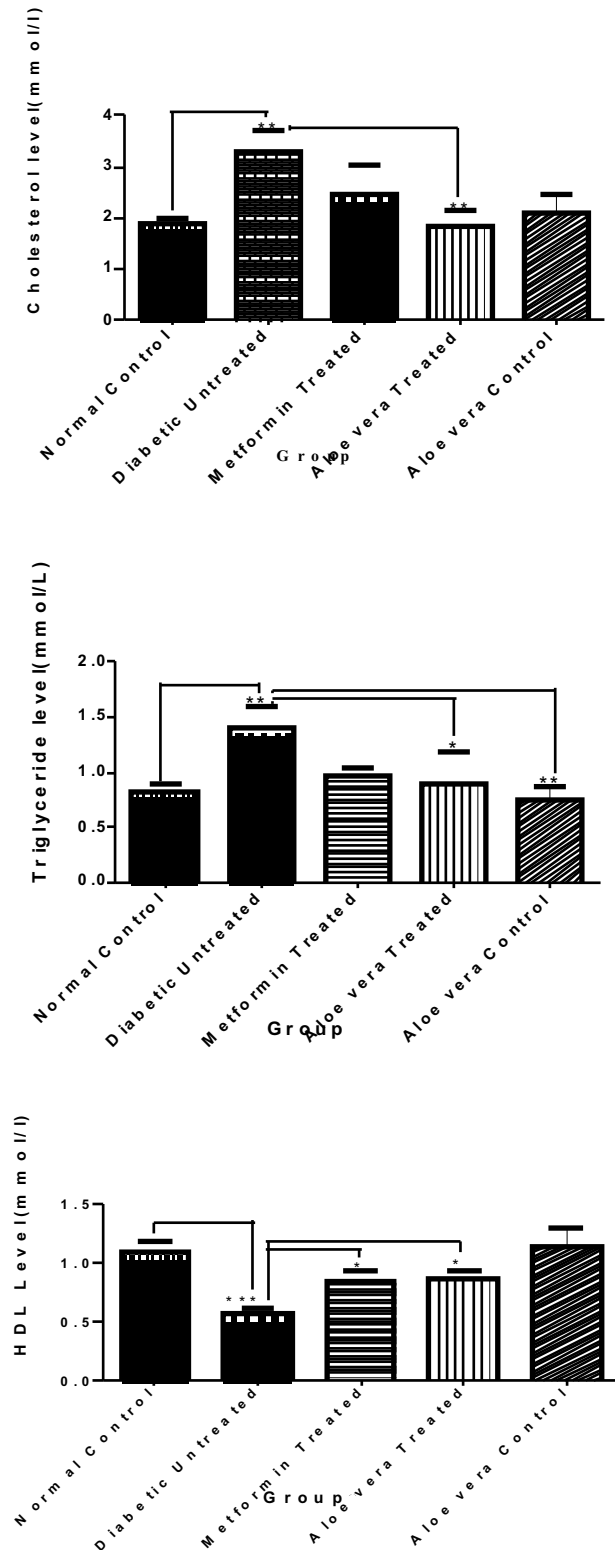
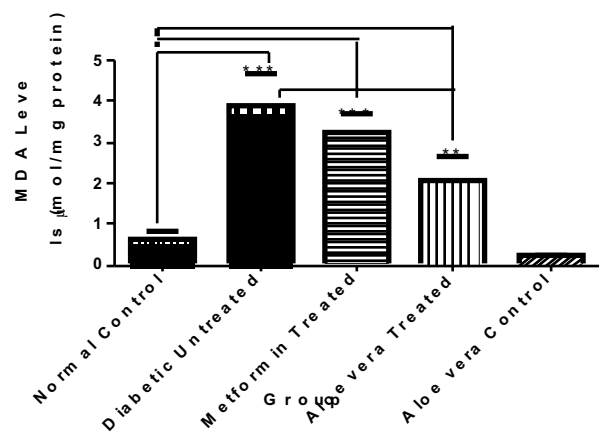


Fig. 2: The Effect of Oral Administration of *Aloe barbadensis* gel on TC, TG, HDL-C and LDL-C in Alloxan-induced Diabetic Rats at the end of a 14-day experimental period (a 2-week study). Data represent means \pm S.D. ($n = 4-6$). Comparison was done between the normal control and diabetic untreated rats, and between Aloe-treated and diabetic untreated rats. NB: * $p < 0.05$, ** $p < 0.01$ and *** $p < 0.001$.

Effect of *Aloe barbadensis* gel on lipid peroxidation and antioxidant enzymes in control and diabetic rats

The levels of lipid peroxidation and activities of antioxidant enzymes in the liver of control and experimental rats are shown in Figure 3. A significant increase in lipid peroxidation was observed in the liver of diabetic untreated rats when compared to normal control group. The activities of SOD, GSH, CAT and GST significantly decreased in the liver of diabetic untreated rats when compared to normal control rats. Whereas in *Aloe vera* gel treated diabetic rats, lipid peroxidation levels were significantly decreased and antioxidant enzymes like SOD, GSH, CAT and GST activities were significantly increased in the liver when compared to diabetic untreated rats.



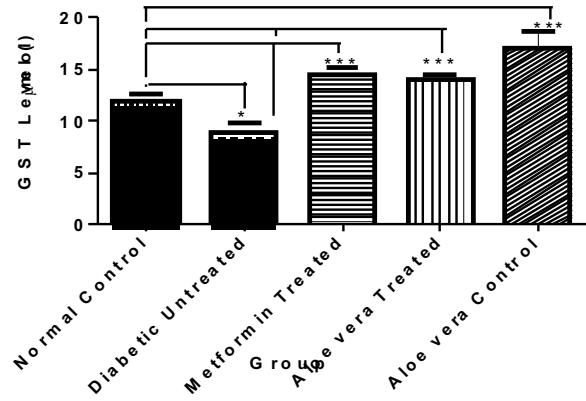
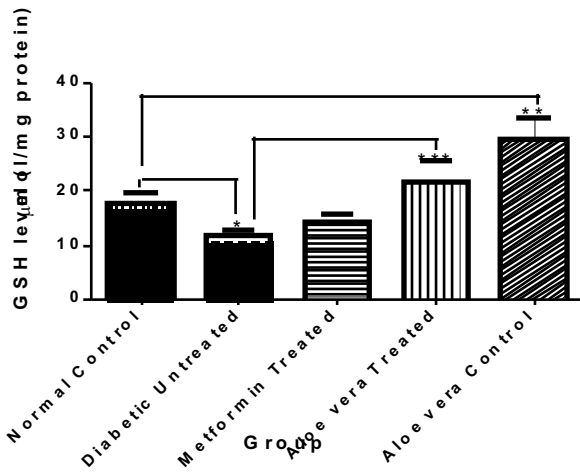
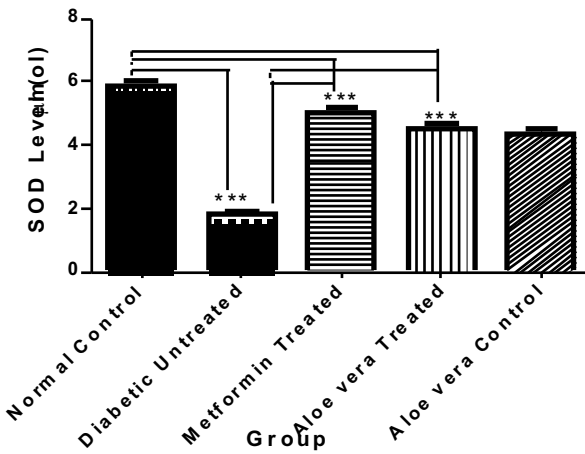
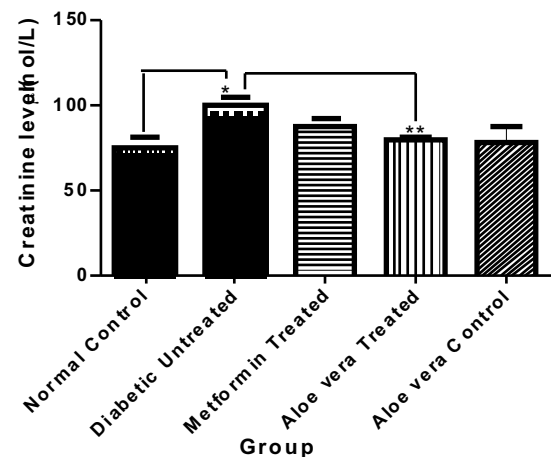
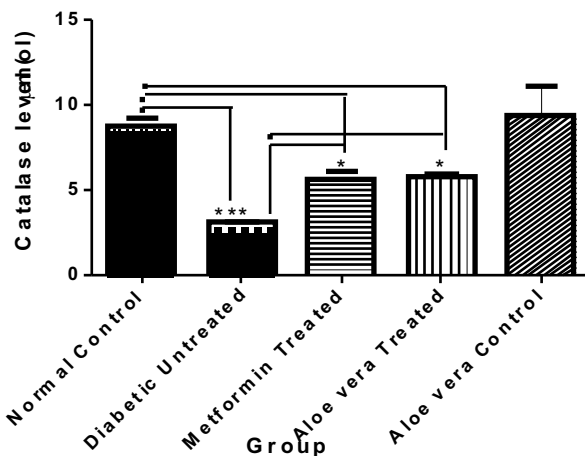
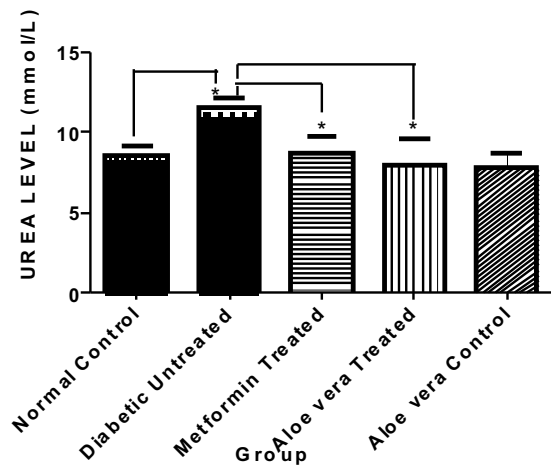
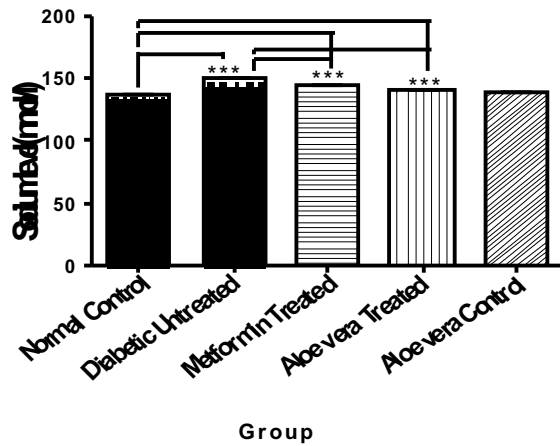


Fig. 3: The Effect of Oral Administration of Aloe barbadensis gel on MDA, GSH, SOD, CAT and GST in the Liver of Alloxan-induced Diabetic Rats at the end of a 14-days experimental period (a 2-week study). Data represent means ± S.D. (n = 4-6). Comparison was done between the normal control and diabetic untreated rats, and between Aloe-treated and diabetic untreated rats. NB: *p<0.05, **p<0.01 and ***p<0.001.



Effect of Aloe barbadensis gel on renal function parameters in control and diabetic rats





Effect of Aloe barbadensis gel on some haematological parameters in normal control and diabetic rats

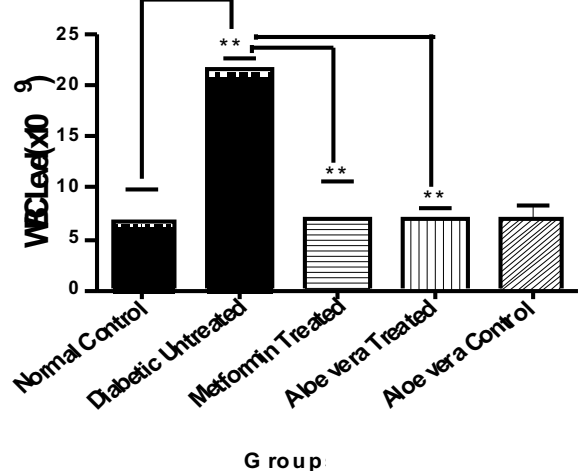
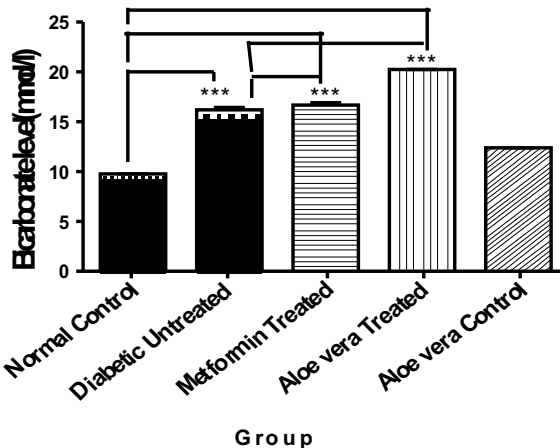
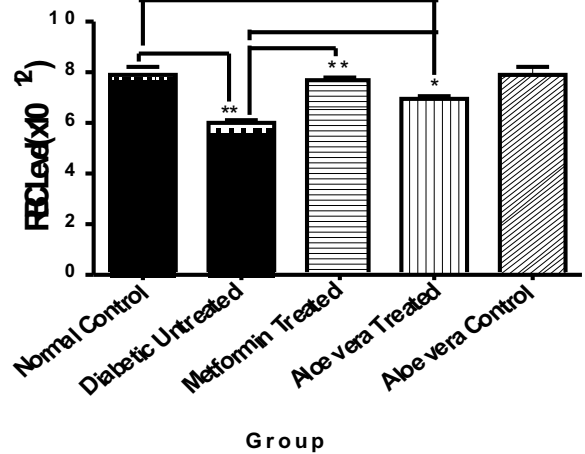
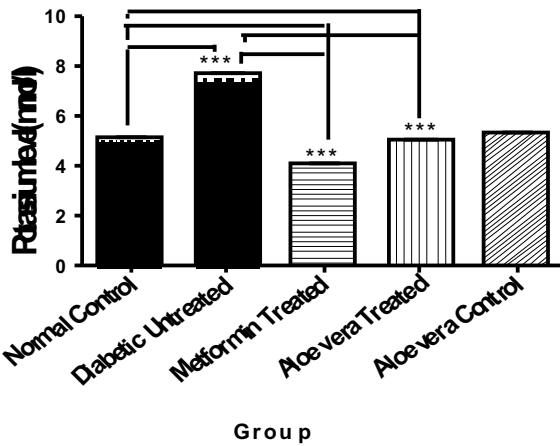
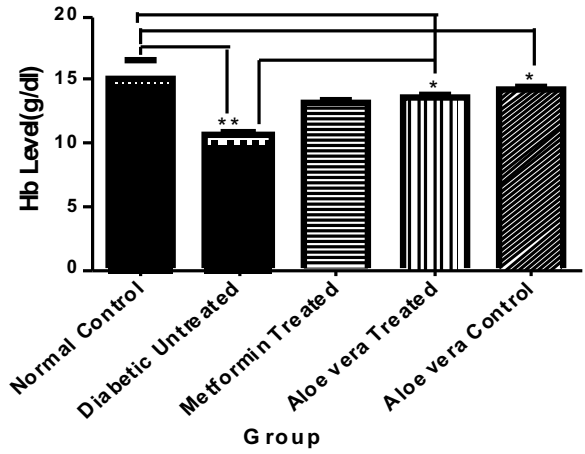


Fig. 4: The Effect of Oral Administration of Aloe barbadensis gel on Urea, Creatinine and some electrolytes in Alloxan-induced Diabetic Rats at the end of a 14-day experimental period (a 2-week study). Data represent means \pm S.D. (n = 4-6). Comparison was done between the normal control and diabetic untreated rats, and between Aloe-treated and diabetic untreated rats. NB: * $p < 0.05$, ** $p < 0.01$ and *** $p < 0.001$.

Fig. 5: The Effect of Oral Administration of Aloe barbadensis gel on HB, RBC and WBC in Alloxan-induced Diabetic Rats at the end of a 14-day experimental period (a 2-week study). Data represent means \pm S.D. (n = 4-6). Comparison was done between the normal control and diabetic untreated rats, and between Aloe-treated and diabetic untreated rats. NB: * $p < 0.05$, ** $p < 0.01$ and *** $p < 0.001$.

Effect of *Aloe vera* gel on histopathological changes in liver and kidney of diabetic Rats.

In control rat, liver cells show normal morphology. In the diabetic rats, few granular hepatocytes (arrow) were observed in the liver of diabetic untreated rats. However, in diabetic rats treated with *Aloe vera* extract moderate amount of congestion was observed in the liver of *Aloe vera* gel treated diabetic rats the liver looking almost normal (Fig.6). In diabetic untreated rat, the kidney tubules show acute tubular necrosis. No abnormality was observed in *Aloe vera* extract treated diabetic rats (Plate 2).

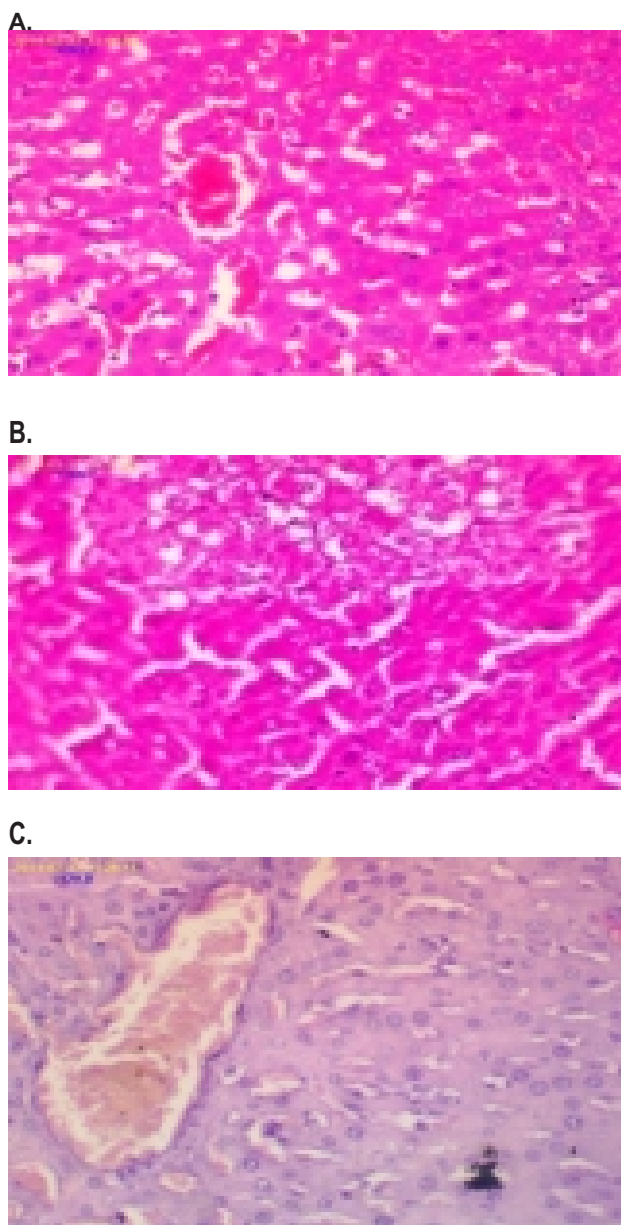


Plate 1: Histological observations of liver of normal control rats, diabetic and *Aloe vera* gel treated diabetic rats (H&E x400).

- A. The liver cells of normal control rats shows normal morphology.
- B. A few granular hepatocytes (arrow) were observed in the liver of diabetic untreated rats.
- C. Moderate amount of congestion was observed in the liver of *Aloe vera* gel treated diabetic rats.

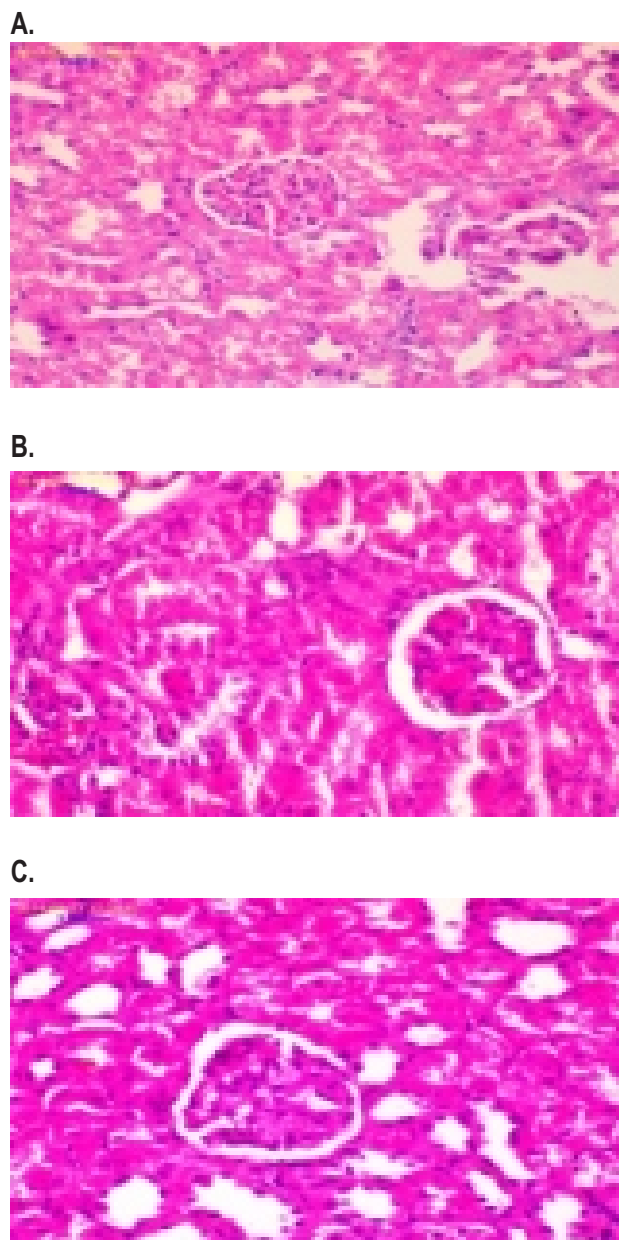


Plate 2: Histological observations of Kidney of normal control rats, diabetic and *Aloe vera* gel treated diabetic rats (H&E x400).

- A. The kidney cells of normal control rat shows normal architecture.
- B. The tubules show Acute tubular necrosis was observed in the kidney tubules of diabetic untreated rats.
- C. No abnormality was observed in kidney of *Aloe vera* gel treated diabetic rats.

DISCUSSION

Diabetes mellitus is a multifunctional disease with several causes and complex consequences. It remains an important risk factor for cardiovascular disease and increasing rate of childhood and adult obesity. Diabetes is likely to become even more prevalent over the coming decade²³. The currently available drug regimens for the management of DM have certain drawbacks and therefore, there is a need to find safer and more effective anti-diabetic therapies²⁴. DM of long duration is associated with several

complications such as atherosclerosis, myocardial infarction, nephropathy etc. These complications have long been assumed to be related to chronically elevated glucose level in blood²⁵.

The results obtained in this study are similar to previous findings^{26,27,28}. Alloxan selectively destroys pancreatic cell, after being taken up by the pancreatic cells via GLUT-2 glucose transporters, alloxan generates reactive oxygen species in a cyclic redox reaction with its reduction product, dialuric acid, auto-oxidation of which generates superoxide radicals, hydrogen peroxide and, in a final iron catalyzed reaction step, hydroxyl radicals. These hydroxyl radicals are ultimately responsible for the death of the β -cells²⁹. In this study, the *Aloe vera* gel demonstrated its antidiabetic properties, significantly lowering blood glucose in the alloxan-induced diabetes to values that were comparable to those of the non-diabetic control consistently for a period of 14 days. The glucose lowering effects were even more pronounced. This result was consistent with other co-workers^{30,31,32}.

The antidiabetic properties of *Aloe vera* is comparable to those of several plants which have been demonstrated to possess hypoglycaemic and antidiabetic actions, for example, significant antidiabetic and antihyperlipidaemic effect was reported with neem seed (*Azadirachta indica*) on alloxan induced diabetes in rats³³, while the leaf extract was found to antagonize the glycogenolytic effects and increased peripheral utilization of glucose by epinephrine in alloxan and streptozotocin induced diabetic and normal rats^{34,35}. Similarly, chronic administration of crude aqueous extracts of *Momordica charantia* and *Swertia chirayita* also showed hypoglycemic effect in streptozotocin treated rats and mice. Although *S. chirayata* was more effective^{8,36}. Hyperlipidemia is a known complication of DM and co-exists with hyperglycemia and is characterized by increased levels of cholesterol, triglycerides and marked changes in lipoprotein fractions. Control of hyperlipidemia is a prerequisite for the prevention of diabetic microangiopathy (retinopathy, nephropathy and neuropathy) and macroangiopathy (ischemic heart disease), cerebral vascular disease and arteriosclerosis obliterans in diabetes⁸. In the present study, elevation in serum lipid profile with concomitant decrease in HDL-C in alloxan-induced diabetic animals is in agreement with previous studies regarding alteration of these parameters under diabetic condition³⁷. The biochemistry of the movement of lipids in the blood stream and the factors that increase lipid deposition in arteries is extremely complex. As far as cholesterol is concerned, the two lipoproteins most concerned with its transport are the high density lipoproteins (HDL) and the low density lipoproteins (LDL). LDL transports cholesterol to the cells where it is deposited even though it may not be required and is therefore associated with atherosclerosis. HDL, on the other hand, transports cholesterol to the liver where it can be removed from the body³⁸. Normally, it is found that high cholesterol levels are associated with high LDL levels, but having a high HDL may compensate for this. In this respect, the markedly increased level of triglycerides and LDL-cholesterol in the serum of diabetic rats of the present work may be a consequence of either over production by the liver or defective removal from the circulation or both secondary to insulin deficiency³⁹. Mechanisms by which HDL decreases in diabetes may be due to the impaired

metabolism of triglycerides rich lipoprotein with decreased activity of lipoprotein lipase and impaired transfer of materials to the HDL components, in addition to the high level of hepatic lipase among diabetics⁴⁰. Thomas showed a strong relationship between high level of total cholesterol concentration in the blood and cardiovascular disorder⁴¹.

Furthermore diabetics have an increased risk of coronary disorder⁴². However, administration of *Aloe vera* significantly reduced the lipid profile level and increased the HDL-C level. These results are similar to previous reports by Rajasekaran *et al.*,⁶, Singh *et al.*,⁴³ and Darokar *et al.*⁴⁴. Traditional plant remedies have been used for centuries in the treatment of diabetes, but only a few have been scientifically evaluated, especially on body tissue of diabetic patient. Therefore, investigation on the effect of *Aloe barbadensis* gel on biomarkers of oxidative stress and the antioxidant enzymes in diabetic rats was carried out. The increase in tissue MDA concentrations (end product of lipid peroxidation) in alloxan-induced diabetic rats along with a significant decrease in the antioxidant SOD activity are in conformation with previous reports documenting elevated serum lipid peroxide levels and diminished antioxidant status in diabetic subjects³⁶. In this study, aloe supplementation results in suppressed free radical-induced oxidative damage. The reduced glutathione (GSH) level, superoxide dismutase (SOD), catalase (CAT) and glutathione-S-transferase (GST) activities were increased in the aloe-treated groups and signs of oxidative tissue damage, such as MDA, were decreased. Can *et al.*,⁴⁵ found similar results in the treatment of neonatal alloxan-induced type diabetic rats. Can *et al.*,⁴⁵ reported that treatment with aloe decreased damage to liver, increased glutathione and decreased lipid peroxidation. Singh *et al.*,⁴³ conducted an extensive study showing that oral dosing with aloe induced the phase II enzyme system (including SOD, CAT and GPx) of mice and significantly reduced lipid peroxidation. In 2002 at the International Aloe Science Council (IASC) Annual Conference, Vinson Joe presented evidence from a human chemical study, that the bio availability of antioxidant supplement vitamins C and E were increased by over 200 percent when taken with *Aloe vera* gel⁴⁶. The decreased activity of antioxidant molecules along with elevated lipid peroxide levels in diabetic rats could probably be associated with oxidative stress and/or decreased antioxidant defense potential has also been reported⁴⁷. The reversal in their contents following treatment may be due to decreased oxidative load. The *Aloe barbadensis* leaf extract may also act by either directly scavenging the reactive oxygen metabolites, due to the presence of various antioxidant compounds or by increasing the synthesis of antioxidant molecules⁴⁸.

CONCLUSION

The results of this study suggest that the medicinal plant, *Aloe vera* may have nutritional remediation qualities, which when used in the right proportion could be of tremendous benefit to the body, including health challenges such as diabetes mellitus (DM) and associated complications, as it produced a palliative effect and a therapeutic effect as observed on blood glucose level and other biochemical and haematological parameters determined.

CONFLICT OF INTEREST

The authors declare no conflict of interest.

REFERENCES

- Whiting, D.R., Guariguata, L., Weil, C., Shaw, J.. IDF Diabetes Atlas: Global estimates of the prevalence of diabetes for 2011 and 2030. *Diabetes Res Clin Pract* 2011, 94:311–321.
- ADA. American Diabetes Association. Diagnosis and classification of diabetesmellitus. *Diabetes Care* 2011, 34(1):S62-69.
- Lionel OP. Metabolic syndrome. *Circulation* 2007, 115: 32-35.
- Asbun, J., Villarreal, F.J. The pathogenesis of myocardial fibrosis in the setting of diabetic cardiomyopathy. *J. Am. Coll. Cardiol.* 2007, 47:693–700.
- Giugliano, D., Ceriello, A. Paolisso, G. Oxidative stress and diabetic vascular complications. *Diabetes Care* 1996, 19:257–267.
- Rajasekaran S, Ravi K, Sivagnanam K, Subramanian S. Beneficial effects of aloe vera leaf gel extract on lipid profile status in rats with streptozotocin diabetes. *Clin Exp Pharmacol Physiol.* 2006, 33:232-237.
- Baynes JW: Role of oxidative stress in development of complications in diabetes. *Diabetes*, 1991, 40, 405–412.
- Oberley, L.W. Free radicals and diabetes. *Free Radical Biol. Med.* 1988, 5: 113-124.
- Bailey, C.J.; Day, C. Traditional plant medicines as treatment for diabetes. *Diabetes Care* 1989, 12, 553–564.
- Tiwari, A.K, Rao, M. Diabetes mellitus and multiple therapeutic approaches of phytochemicals: Present status and future prospects. *Curr. Sci.* 2002, 83:30-38.
- Ugochukwu, N. H., Babady, N. E., Cobourne, M., Gasset, S. R.. The effect of *Gongronema latifolium* extracts on serum lipid profiles and oxidative stress in hepatocytes of diabetic rats. *J. Bioscience* 2003, 28: 1-5.
- Helal, EGE. Mohammed HA. Asharf MM. and Al-Kamel A. Effect of Aloe vera extract on some physiological parameters in diabetic albino rats. *Egyptian J. of Hosp. Med.* 2003, 12: 53-61.
- Boudreau MD, Beland FA. An evaluation of the biological and toxicological properties of Aloe vera. *J. Environ Sci Health C. Environ Carcinog Ecotoxicol Rev* 2006, 24 (1): 103-154
- Vogler, B.; Ernst, E.. *Aloe vera*: A systematic review of its clinical effectiveness. *Br. J. Gen. Pract.* 1999, 49, 823–828.
- Hamman, J.H. Composition and applications of *Aloe vera* leaf gel. *Molecules* 2008, 13:1599–1616.
- Abuelgasim, A.I.; Osman, M.K.M.; Elmahdi, B. Study on the effects of *Aloe vera* (elsabar) ethanolic extract on blood glucose level in wister albino rats. *J. Appl. Sci. Res.* 2008, 43, 1841–1845.
- Van Kampen, E.J.; Zijlstra, W.G. Standardization of hemoglobinometry. II. The hemoglobincyanide method. *Clin. Chim. Acta* 1961, 6, 538–544.
- Lowry OH, Rosenbrough NJ, Farr AL, Randall R. Protein determination using Folin-Cicalteu reagent. *J Biol Chem* 1951, 193:265–278.
- Okhawa H, Ohishi N, Yagi K. Assay of lipid peroxides in animal tissues by thiobarbituric reaction. *Anal Biochem.* 1979, 95:351–358.
- Beutler E., Duron O., Kelly, B.M. Improved Method for the Determination of Blood Glutathione," *Journal of Laboratory and Clinical Medicine* 1963, 61(3):882-888.
- Takahara S, Hamilton BH, Nell JV, Ogura Y, Nishimura ET Hypocatalasemia, a new genetic carrier state. *J Clin Invest* 1960, 29:610–619.
- Misra HP, Fridovich I. The role of superoxide anion in the autoxidation of epinephrine and a simple assay of superoxide dismutase. *J Biol Chem* 1972, 247:3170–3175.
- Afaf I, Maha KMO, Elmahdi B *Journal of Applied Sciences Research.* 2008, 4: 1841-1845.
- Grover JK, Yadav S, Vats V. Medicinal plants of India with antidiabetic potential. *J Ethnopharmacol.* 2002, 81:81-100
- Beppu H, Koik T, Shimpo K, Chihara T, Hoshino M, Ida C, Kuzuya H. Radical scavenging effects of *Aloe arborescens* Miller on prevention of pancreatic islet β -cell destruction in rats. *J Ethnopharmacol.* 2003, 89:37-45.
- Chika A, Bello SO. Antihyperglycaemic activity of aqueous leaf extract of *Combretum micranthum* (Combretaceae) in normal and alloxan-induced diabetic rats. *J Ethnopharmacol.* 2010, 129:34-37.
- Jain DK, Arya RK. Anomalies in alloxan-induced diabetic model: It is better to standardize it first. *Indian J Pharmacol.* 2011, 43:91.
- Maiti R, Jana D, Das UK, Ghosh D. Antidiabetic effect of aqueous extract of seed of *Tamarindus indica* in streptozotocin-induced diabetic rats. *J. Ethnopharmacol.* 2004, 92(1):85-91
- Lensen S. Mechanism of Alloxan and Streptozocin induced diabetes. *Diabetologia* 2008, 51:216-226
- Kim, K.; Kim, H.; Kwon, J.; Lee, S.; Kong, H.; Im, S.A.; Lee, Y.H.; Lee, Y.R.; Oh, S.T.; Jo, T.H. Study on the hypoglycemic and hypolipidemic effects of processed *Aloe vera* gel in a mouse model of niddm. *Phytomedicine* 2009, 16:856–863.
- Mohamed AE, Abdel-Aziz AF, El-Sherbiny EM, Morsi RM.. Anti-diabetic effect of aloe vera juice and evaluation of thyroid function in female diabetic rats. *Bioscience Research* 2009, 6:28-34.
- Liao Z, Chen M, Tan F, Sun X , Tang K. Micropropagation of endangered Chinese aloe. *Plant Cell Tissue and Organ Culture* 2004, 76 (1); 83-86
- Chttopadhyay RR. Possible mechanism of antihyperglycemic effect of *Azadirachta indica* leaf extract. Part IV. *Gen Pharmacol.* 1996, 27:431-434.
- Bopanna KN, Kannan J, Sushma G, Balaraman R, Rathod SP. Antidiabetic and antihyperlipaemic effects of neem seed kernel powder on alloxan diabetic rabbits. *Indian J Pharmacol.* 1997, 29:162-7.
- Akinyele BO, Odiyi AC. Comparative study of the vegetable morphology and the existing taxonomic status of *Aloe vera* l., *Journal of Plant Science* 2007, 2 (5): 558-563
- Banerjee S, Sengupta A, Banerjee J, Adhikary P, Chatterjee A. Studies on hypoglycemic effect of indigenous herbs. *Indian J Pharmacol* 1994, 26:229-30.
- Eshun K, He Q. *Aloe vera*; a valuable ingredient for the food, pharmaceutical and cosmetic industries- a review. *Crit. Rev Food Sci Nutr.* 2004, 44 (2): 91-96
- Allan G, Shane B, Manias E, Barry H, Richards A. *Fundamentals of Pharmacology: An applied approach for nursing and health.* 4th edition. Pearson Education Australia. 2007, p413-542.
- Capeau J. Insulin resistance and steatosis in humans. *Diabetes Metab.* 2008, 34:649-57.
- Balkis Budin S, Othman F, Louis SR, Abu Bakar M, Radzi M, Osman K, Das S, Mohamed J. Effect of

- alpha lipoic acid on oxidative stress and vascular wall of diabetic rats. *Rom J Morphol Embryol.* 2009, 50:23-30.
41. Thomas RM.. Oxidative stress and lipid in diabetes. A role in endothelium vasodilator dysfunction. *Physiology Research.* 2002, 50: 536-546.
 42. Davis TM, Cull CA, Holman RR. Relationship between ethnicity and glycaemia control, lipid profiles, and blood pressure during the first 9 years of type 2 diabetes: UK Prospective Diabetes Study (UKPDS 55). *Diabetes Care* 2001, 24:1167–74.
 43. Singh, M., Dhanalakshmi, E., Rao, M. Chemomodulatory action of *Aloe vera* on the profiles of enzymes associated with carcinogen metabolism and antioxidant status regulation in Mice. *Phytomedicine* 2000, 28: 317-324
 44. Darokar MP , Rai R, Gupta AK, Shasany AK Rajkumar S, Khanuja SP. Molecular assessment of germplasm diversity in *Aloe spp* using FAPD and AFLP analysis. *J. Med Arom Plant Sci* 2003, 25 (2): 354-361
 45. Can, A., Akev, N, Baktir, G.. Effect of *Aloe vera* leaf Gel and pulp extracts on the liver in Type – II Diabetic Rats Models. *Biol. Pharm. Bull.* 2004, 82: 211-225.
 46. Vinson, J.A.; Al Kharrat, H.; Andreoli, L. Effect of *Aloe vera* preparations on the human bioavailability of vitamins C and E. *Phytomedicine* 2005, 12, 760-765.
 47. Mahdi, A.A.. Free radicals and other antioxidants. A textbook of Biochemistry by S.P. Singh, 3rd Edn. CBs Publishers and Distributors. New Delhi, 2002, pp545-555
 48. Gupta, S.K. Prakash, J. and Srivastava, S. Validation of traditional claim of Tulsi, *Ocimum sanctum* Linn. as a medicinal plant. *Indian J Exp Biol.* 2002, 40(7): 765-7